

BEHÇET'S SYNDROME

Definition

Behçet's Syndrome is an inflammatory disorder, now considered as a systemic vasculitis of uncertain aetiology, characterised by a very wide spectrum of clinical features and by unpredictable exacerbations and remissions.

This condition was first recognised in ancient Greece by Hippocrates in the 5th century BC. The condition was later described by the Greek ophthalmologist Benedict Adamantiades (1931), and six years later by the Turkish dermatologist Hulusi Behçet. As a result some authors prefer the term "Adamantiades-Behçet Syndrome". However, it was Behçet who also described the classical clinical triad of oral and genital ulceration with ocular inflammation.

The main manifestations of Behçet's disease are recurrent oral and genital ulceration, eye problems and skin lesions. However, nearly all organs and systems can be affected by this widespread vasculitis, and hence the features of this condition may be multiple and varied.

Epidemiology

Behçet's Syndrome occurs throughout the world with varying prevalence. It is uncommon in Western Europe and the USA (from 0.1 to 7.5 patients per 100.000 inhabitants), while being more prevalent in the Mediterranean Countries, South East Asia (2-20/100.000), in the so-called "silk route" countries (13-370/100.000) and particularly in countries such as Japan (13-30/100.000) and Turkey (80-370/100.000). There is also an increased prevalence in certain ethnic groups, while the prevalence of the disease is also dependent on the geographic area of their residence.

Onset of disease can occur at any age, but is typically in the third decade of life. The clinical picture may take some time to develop but is usually complete in a mean of 15 months from the time of onset. Few neonatal cases have been reported, and children are rarely affected. Young patients have the same presentation, while early onset and male gender are associated with more severe disease. Both genders are equally affected, although large series of patients in certain Mediterranean countries and the Middle East showed that there is a male predominance (1.5-5:1). Familial occurrence has been reported in 1 to 18% percent of patients, mostly of Turkish, Israeli and Korean origin.

Clinical presentation

The multiple manifestations of Behçet's Syndrome have been traditionally divided into major features (oral ulceration, genital ulceration, inflammatory eye disease and skin lesions) and minor (arthritis, neurological involvement, peripheral arterial and venous disease, gastrointestinal and pulmonary or renal involvement), based on their frequency and not on their clinical severity. The relative frequency of these manifestations varies geographically.

Recurrent oral ulceration is the most common feature of Behçet's Syndrome (95-100%). Clinically the oral lesions are similar to those that may be observed in patients with Recurrent Aphthous Stomatitis and may be also classified into minor, major or herpetiform. Minor ulcers (< 1 cm.) are rounded or oval, shallow, covered by whitish or greyish pseudomembrane and surrounded by an erythematous halo. Major ulcers are larger (>1 cm.), deeper, more painful and heal more slowly, often with scarring.

Herpetiform ulcers are uncommon, more numerous (from 10 to 100) and smaller (1-2 mm.) although lesions may occasionally become confluent and form larger lesions.

Genital ulcers (57-93%) are painful and morphologically similar to oral lesions. The most frequently involved sites are the scrotum and penis in males and the labia in females. Deep ulcers may cause discomfort in sitting down and walking or cause dysuria or dyspareunia and usually heal with scarring.

Ocular lesions (30-90%) occur in the uvea and retina. Lesions are usually bilateral, although the severity may be asymmetrical. Patients usually present within the first 2 or 3 years of the onset of the disease and may experience sudden attacks of visual loss, blurred vision and associated eye pain. Isolated anterior uveitis and hypopyon are not infrequent and are relatively benign lesions. Severe ocular complications may present including retinal detachment, glaucoma, cataract or blindness.

Skin lesions (38-99%) can be divided into two main types, erythema nodosum-like lesions and papulopustular or acneiform lesions. Both types can occur in either gender with erythema nodosum-like lesions more frequent in female patients and usually occurs on the front of the legs. These lesions are painful and resolve spontaneously leaving deeply pigmented areas and sometimes ulceration. Papulopustular or acneiform lesions are more common in male patients and are usually found on the back, face and neck and should be differentiated from adolescent acne.

The primary lesion in Behçet's Syndrome is vasculitis and vessels of all kind and size may be affected. Peripheral arterial and venous disease may cause embolization, occlusion and pseudoaneurysms.

Generally, arthropathy (16-84%) in Behçet's patients shows a non-erosive, non-deforming and oligoarticular or monoarticular pattern.

Different vasculitis-related neurological, gastrointestinal, cardiovascular and pleuropulmonary lesions may be observed in Behçet's patients. Some of them may lead to serious complications.

Aetiopathogenesis

At present, Behçet's Syndrome cannot be classified as a hereditary disease nor as an infectious disease or an autoimmune disorder, and is best described as a multifactorial condition arising from a combination of endogenous and exogenous factors. Familial cases (1-18%) are relatively uncommon and Behçet's Syndrome does not follow a Mendelian pattern. It is therefore difficult to attribute the aetiopathogenesis to genetic factors alone.

Susceptibility to Behçet's Syndrome is strongly associated with the Human Leukocyte Antigen HLA-B51, particularly in patients from Japan, Mediterranean and Middle Eastern Countries. HLA-B51 is more common in males than in females and is also associated with ophthalmic and more severe disease. Other HLA antigens have shown interesting relations with this condition. Thus, HLA-B27 is closely related to arthritic lesions and HLA-B12 to mucocutaneous lesions. Current research in this area includes investigation into new genetic factors and markers (HLA-DRw8 or HLA-B15, variants of ICAM-1 gene or MIC-A gene and many others) and to understand the role they play. Overall the evidence of an infectious cause is still inconclusive. There is some evidence that microbial infections may trigger cross-reactive autoimmune responses, leading to overt Behçet's Syndrome. Interestingly Behçet suggested a viral aetiology in his original publication. Several studies have identified herpes simplex virus type 1 (HSV1) DNA in peripheral blood lymphocytes and monocytes or serum antibodies to HSV1 in a high proportion in Behçet's patients, but not in a proportion statistically significant in biopsy samples from oral ulcers. *In vitro* studies suggest that a possible hypersensitivity to certain *Streptococcus sanguis* antigens may play a part in the pathogenesis.

The presence of increased levels of circulating IgG immune complexes, particularly during symptomatic periods, but without deposition observed in biopsy samples from lesions, decreased lymphocytes T helper (T4) / T suppressor (T8) ratio, decreased activity of NK cells or increased levels of interleukin IL-10, and IL-2 have been reported in several studies. However, there is no definitive consensus about how these findings are linked to the pathogenesis.

Diagnosis

There are no specific laboratory tests to confirm the diagnosis of Behçet's Syndrome.

In the absence of a significant pathognomonic finding, the diagnosis of Behçet's Syndrome depends entirely on careful history-taking and clinical findings. Different international classification criteria have been developed to ensure comparability of groups of patients for research and to provide greater objectivity to the diagnosis. The guidelines proposed by International Study Group for Behçet's Disease are the most commonly used for research purposes. These criteria require recurrent oral ulceration as an essential symptom, plus two or more of the following symptoms: recurrent genital ulceration, ocular lesions, skin lesions or positive pathergy test (table 1). Despite the numerous diagnostic criteria published, problems still arise as features may not be present at the same time and incomplete forms of the condition may occur.

The differential diagnosis of Behçet's Syndrome includes recurrent aphthous stomatitis, viral infections, Reiter's Syndrome, Stevens-Johnson's Syndrome, inflammatory bowel disease, PFAPA Syndrome, MAGIC Syndrome, Sweet's Syndrome, sarcoidosis, multiple sclerosis, and HLA-B27 related syndromes such as ankylosing spondylitis.

The pathergy test is performed by piercing a sterile 20-gauge needle subcutaneously into the forearm, without injection of saline. It is considered as positive when the puncture leaves an aseptic erythematous nodule or pustule larger than 2 mm. in diameter after 24 or 48 hours. At one time the pathergy test was thought to be diagnostic, but has been shown to be unreliable in terms of both its specificity and its geographical variability. Indeed only 20-60% of Behçet's patients present positive pathergy tests.

Treatment

In the absence of understanding of the aetiopathogenesis and knowledge of a curative therapy, the management of these patients is directed at the control of the symptoms and to suppress the inflammatory vasculitis. There is no established standard therapeutic regimen due to the variability of clinical manifestations of each individual patient. The choice of the treatment depends on the clinical features and is best managed by a multidisciplinary team.

Oral ulcers are treated in a similar way as those that recurrent aphthous stomatitis patients present. Generally, the less severe cases are treated with topical corticosteroids such as triamcinolone acetonide (0.05-0.5%), betamethasone (0.05-0.1%) or clobetasol propionate (0.05%) in ointments or in mouthwashes. Prednisone (5 mg./20ml. of water) or sucralfate suspensions mouthwashes or topical administration of Amlexanox (5%) are other treatment possibilities. Severe cases are treated by the systemic administration of immunomodulatory drugs (colchicine, prednisone,

azathioprine, ciclosporin, mycophenolate mofetil, tacrolimus, thalidomide, dapsone, pentoxifylline, methotrexate, cyclophosphamide or interferon-alpha) administered by appropriately qualified clinicians and in such a way as to minimise the risk of unwanted secondary effects.

Genital and skin lesions must be kept clean to avoid contaminated secondary infection. There are usually managed with topical corticosteroids or corticosteroids in combination with antibiotics. Lesions at multiple sites may require systemic therapy. The treatment of ocular lesions requires careful consideration in collaboration with an ophthalmologist. Colchicine, topical mydriatics and corticosteroids are prescribed for the treatment and prevention of anterior uveitis. Acute posterior uveitis attacks are treated using high doses of corticosteroids or ciclosporin. In certain cases other immunomodulating medications may be required.

The treatment of other manifestations of this syndrome is based on the usage of different combinations of anti-inflammatory analgesics, corticosteroids and immunosuppressive agents and even surgical intervention if appropriate. Therapeutic priority is given to the treatment of vital organ lesions.

Prognosis and complications

Behçet's Syndrome runs a chronic course with unpredictable exacerbations and remissions. The frequency and severity of attacks may reduce with time, but there is no possible way of predicting the evolution of these patients in terms of morbidity and possible mortality. Young onset and male patients have been shown to confer a worse prognosis while a severe deterioration is seen in 20% of patients. Some possible complications include bowel perforation, extensive thrombotic events, or rupture of arterial aneurysms and may lead to death. Fortunately mortality does not appear to be higher than in general population.

Morbidity, however, may be high and may lead to significant disabilities. Irreversible retinal vasculitis and blindness, sterile meningoencephalitis or severe arthritis may occur and are severe complications of Behçet's syndrome.

Behçet's syndrome is still one of the most frequently encountered causes of endogenous uveitis. The introduction of ciclosporin has greatly assisted in the management, and prognosis of visual manifestations. The encouraging results with the use of Interferon-alpha in the treatment of this syndrome may further improve the prognosis in certain cases, particularly when further research on dosage standardization has been completed.

The treatment of the mucocutaneous and eye manifestations has improved significantly in recent years. However, arterial or neurological manifestations may still present significant management problems.

Prevention

The unknown aetiology of Behçet's Syndrome is a significant handicap in the development of a preventative regimen for the disease. In absence of such knowledge and of a curative therapy, treatment is directed at the relief of symptoms and the prevention of complications. A multi-system disorder such as this is best managed with input from a multidisciplinary to ensure optimal outcome. All the immunomodulating agents that are used to prevent the attacks of the disease and complications have short and long-term secondary effects. Only a rigorous planning and dosage will minimize undesirable effects.

There is conflicting opinion on whether Behçet's patients should or should not be anticoagulated. Whilst anticoagulation may reduce the risk of thrombosis or embolism, it increases the risk of serious haemorrhage and is contraindicated in case of previous or suspected aneurysm formation. As such each case should be considered on its own merits.

Table 1 Diagnostic criteria for Behçet disease

Recurrent oral ulceration	Minor aphthae, major aphthae or herpetiform ulceration observed by physician or patient
Plus 2 of:	
Recurrent genital ulceration	Aphthous ulceration or scarring observed by physician or patient
Ocular lesions	Anterior uveitis, posterior uveitis, or cells in vitreous humour on slit lamp examination or retinal vasculitis observed by ophthalmologist
Skin lesions	Erythema nodosum, pseudofolliculitis or papulopustular lesions examined by physician Acneform nodules observed by physician in patients not on steroid treatment
Positive pathergy test	Checked by physician at 24-48 hours

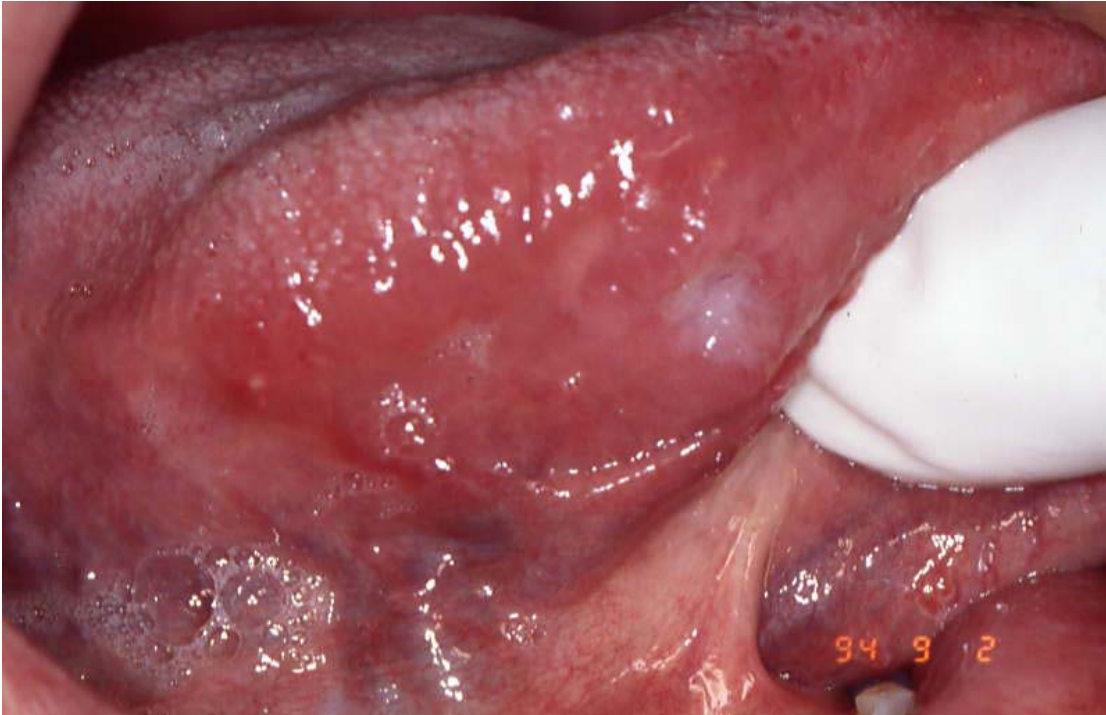


Figure 1. Oral lesion in a patient affected by Behçet's syndrome

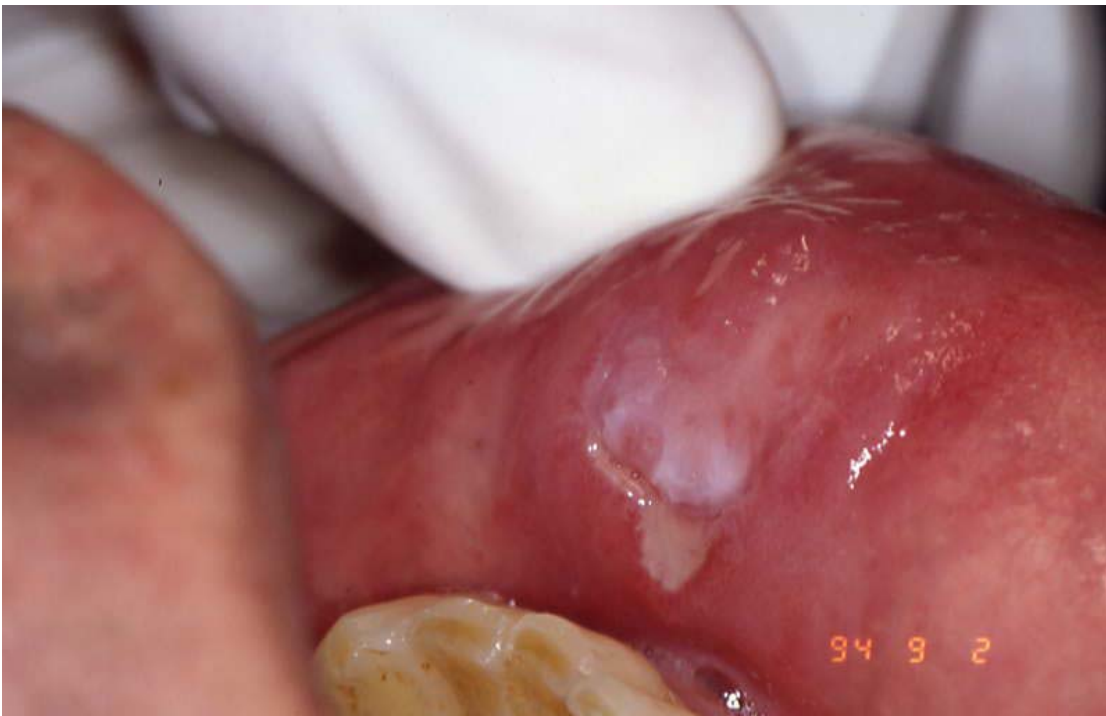

Figure 2. Labial lesion in a patient affected by Behçet's syndrome

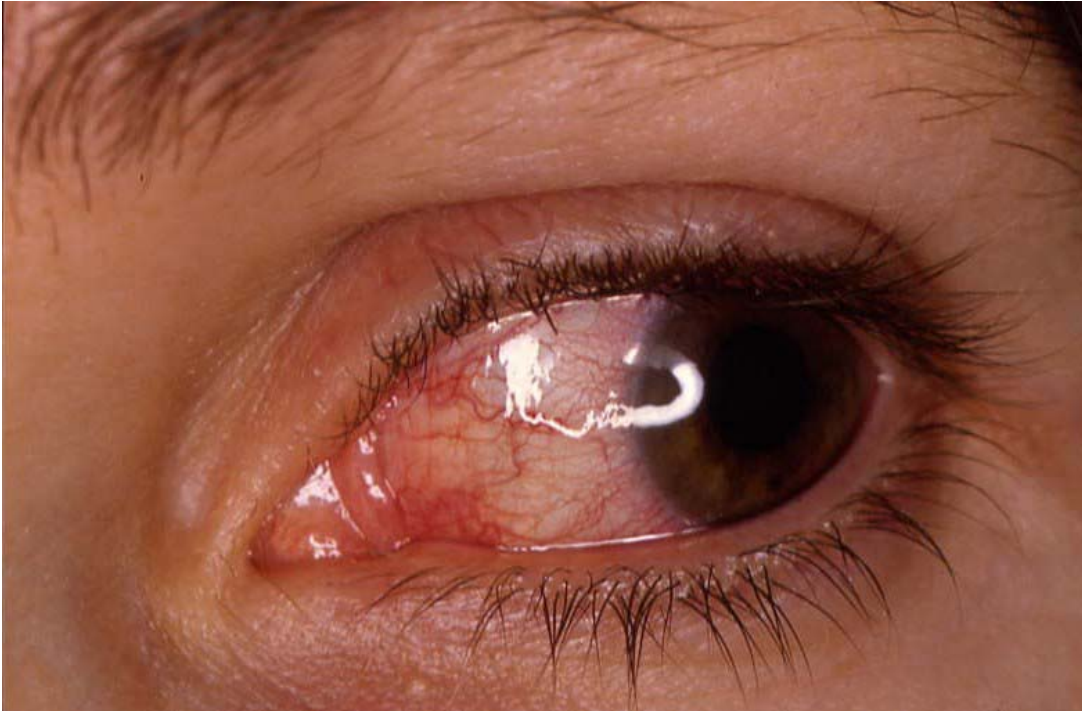

Figure 3. Eye lesions in a patient affected by Behçet's syndrome

Further reading

- 1 International Study Group for Behçet's Disease. Evaluation of diagnostic (classification) criteria in Behçet's syndrome – towards internationally agreed criteria. *Br J Rheumatol* 1992; 31: 299-308.
- 2 Barnes CG, Yazici H. Behçet's Syndrome. *Rheumatology* 1999; 38:1171-76.
- 3 Whallet AJ, Thurairajan G, Hamburger J, Palmer RG, Murray PI. Behçet's syndrome: a multidisciplinary approach to clinical care. *Q J Med* 1999; 92: 727-40.