

GEOGRAPHIC TONGUE

Definition

Geographic tongue is a fairly common, usually painless inflammatory disorder that affects mainly the dorsum of the tongue. The pattern of the lesions give the surface of the tongue the appearance of a map, hence the term «geographic». Since the first description in 1831, other terms related to this condition have been: benign migratory glossitis, glossitis areata migrans, wandering rash of the tongue, erythema migrans, stomatitis and erythema areata migrans. As no risks or consequences have been associated with this condition, the term benign should be accepted for this disorder.

Epidemiology

Geographic tongue occurs in approximately 3% of the population worldwide. In epidemiological reports the prevalence of the condition varies between 0.28% and 14.4% in all age groups, although it occurs more commonly in adults than in children. Females are affected twice as often as males. There is no apparent racial or ethnic predilection.

Clinical presentation

Geographic tongue presents with one or more irregular, well-defined red areas, most commonly surrounded by a raised white-greyish margin on the dorsum and/or borders of the tongue. The smooth red patches can have various shapes and size and are due to a localized desquamation with loss of tongue filiform papillae. The tongue papillae appear hyperkeratotic in the margins of the red denuded lesions, while fungiform and other tongue papillae are unaffected. Usually, the lesions persist for a short period in one area, disappear within a few days, and then recur in another area with no apparent reason. The disease is characterized by periods of exacerbation and remission, during which lesions heal without residual scar formation. These may last days, months, or years. Continuously changing patterns and migration of lesions on the tongue surface with unusual appearance of the tongue are the main complaint. Patients usually refer no painful symptoms nor taste loss, but slight irritation to increased sensitivity in the affected areas are sometimes reported, particularly with salty, spicy and acidic foods.

Geographic tongue is often associated with fissured tongue, although the cause is still unknown. Very rarely, circinate red areas with whitish borders similar to the typical tongue lesions can occur in other areas of the mouth mucosa, mainly in the labial vestibular and buccal mucosa. In this cases the condition is best defined as geographic stomatitis.

Etiopathogenesis

The cause of geographic tongue is unknown, but a strong familiarity has been reported. A polygenic inheritance and the association with a number of other genetic or medical conditions has been suggested. In particular, an increased frequency is observed in patients with psoriasis; otherwise the great majority of those with geographic tongue do not develop psoriasis. Moreover these two conditions share histopathologic similarities. Inflammation characterizes the histology of the red depapillated areas of geographic tongue with loss of keratin, neutrophils, lymphocyte and plasma cells infiltrate and intraepithelial microabscesses.

Geographic tongue is not an infectious disease nor it is related to systemic infections like HIV. It is not transmissible between partners.

It is not linked to the use of tobacco but it has been reported as a rare side effect of lithium treatment.

Geographic tongue is more common in people with allergic diseases such as atopy, asthma, eczema and contact allergy but a clear pathogenic link with allergy has not been actually demonstrated.

Hypersensitivity to dental materials may contribute to the etiology or the exacerbations of the condition, but no definitive evidences are available.

Precipitating factors that stimulate lesion formation and/or subjective complaints include stress, gastric diseases, alcoholic beverages, salty, spicy and acidic foods, and other local irritants such as some ingredients of toothpastes.

The observed effect of oral contraceptives in young women on the lesions of geographic tongue suggested a role for hormone levels in the expression of the condition.

Diagnosis

Diagnosis of geographic tongue is based on the clinical aspect of lesions and patient history and seldom requires histologic confirmation. Geographic tongue should be differentiated from candidiasis, leukoplakia, contact allergy, lichen planus, lupus erythematosus and trauma. Once the diagnosis is made, the patient should be informed about causative factors, the course of the condition and its benign nature.

Treatment

When asymptomatic, geographic tongue requires no treatment. Anxious and cancerophobic patients should be treated with reassurance and local measures. Several treatments have been suggested in symptomatic patients. Oral hygiene and mild mouthrinses should help in cleaning the mucosal surfaces and reducing the discomfort. Topical retinoids are the most

successful but have transient effect. Topical anaesthetics, topical corticosteroids, antihistamines and antifungals may be used to alleviate burning symptoms.

A very few patients with geographic tongue are zinc deficient; if low zinc levels are demonstrated, zinc supplementation should help.

Prognosis and complications

Geographic tongue is a benign condition that never turns into malignancy. There are also no reported consequences nor risks associated with this condition. The only complication is the discomfort due to the persistent clinical appearance and frequent recurrence after healing.

The reported association between geographic tongue and allergic diseases could sometimes suggest the dental practitioner should obtain medical advice for the affected patient.

Prevention

As the cause is unknown, the condition is not preventable. However it is advisable to promote optimal oral hygiene and avoid contact with local factors that could precipitate symptoms, such as spicy and acidic foods, alcohol, irritants in toothpastes and mouthrinses.

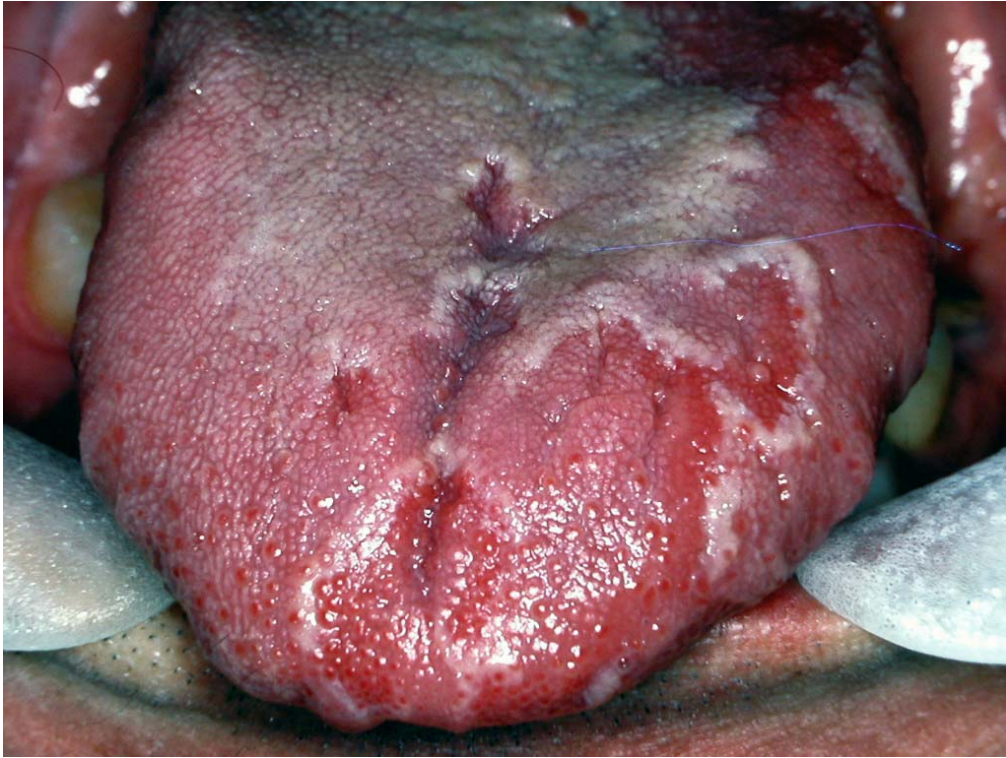


Figure 1. Clinical appearance of a geographic tongue with denuded areas delimited by hyperkeratotic borders

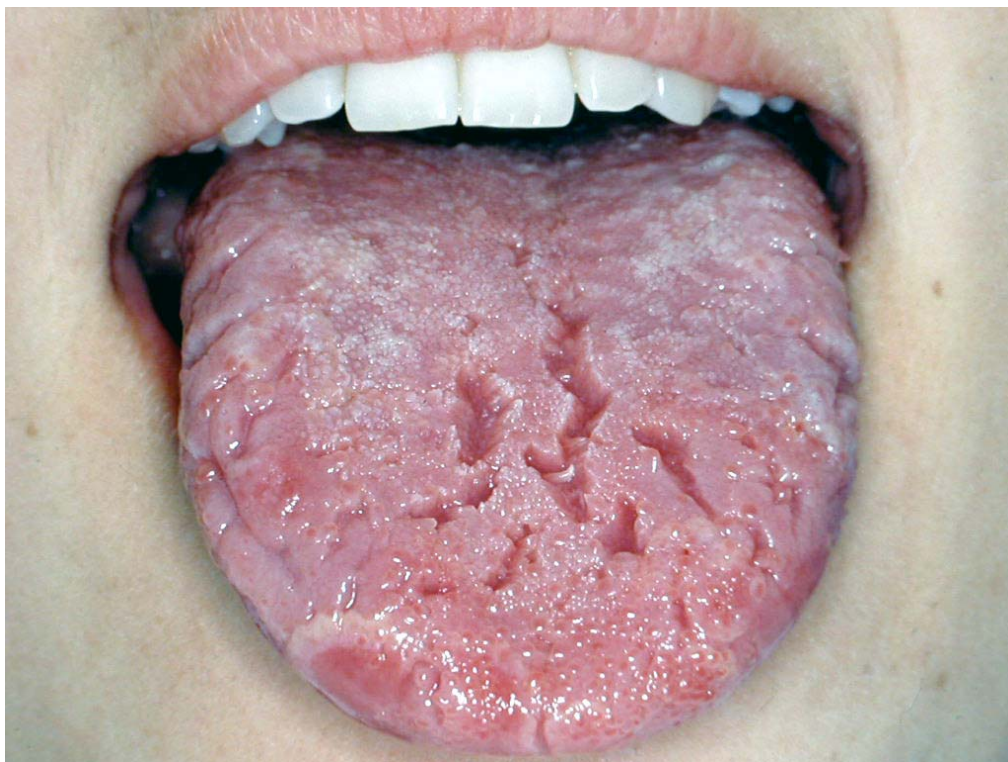


Figure 2. geographic tongue associated with fissures of the dorsum

Further reading

- 1 Assimakopoulos D, Patrikakos G, Fotika C and Elisaf M. Benign migratory glossitis or geographic tongue: an enigmatic oral lesion. *Am J Med* 2002; 113:751-5
- 2 Axéll T. Hypersensitivity of the oral mucosa: clinics and pathology. *Acta Odontol Scand* 2001; 59:315-9
- 3 Femiano F. Geographic tongue (migrant glossitis) and psoriasis. *Minerva Stomatol* 2001; 50:213-7
- 4 Fenerli A, Papanicolaou S, Papanicolaou M and Laskaris G. Histocompatibility antigens and geographic tongue. *Oral Surg Oral Med Oral Pathol* 1993; 76:476-9
- 5 Gibson J et al. Geographic tongue: the clinical response to zinc supplementation. *J Trace Elem Experim Med* 1990; 3:203-8.
- 6 Waltimo J. Geographic tongue during a year of oral contraceptive cycles. *Br Dent J* 1991; 171:94-6

Links

[http:// www.eastman.ucl.ac.uk/~eaom/info-leaflets/cms-leaflets/GEOGRAPHIC TONGUE.pdf](http://www.eastman.ucl.ac.uk/~eaom/info-leaflets/cms-leaflets/GEOGRAPHIC_TONGUE.pdf)

[http://www.usc.edu/hsc/dental/opath/cards/geographic tongue.html](http://www.usc.edu/hsc/dental/opath/cards/geographic_tongue.html)

<http://www.emedicine.com/derm/topic664.html>