

## **ORAL BIOPSY**

### **Definition**

There are oral lesions whose diagnosis can be made relying on data gathered during the history and/or physical examination, but there are others where histopathological studies are needed to confirm the presumed clinical diagnosis.

Biopsy is a surgical procedure to obtain tissue from a living organism for its microscopical examination, usually to perform a diagnosis

### **Objectives**

The aim of the biopsy is to:

- define a lesion on the basis of its histopathological aspect;
- to establish a prognosis in malignant or premalignant lesions;
- facilitate the prescription of specific treatment;
- contribute to the assessment of the efficacy of the treatment;
- act as a document with medical-legal value.

### **Indications**

Biopsy is indicated for diagnostic confirmation of suspected malignant lesions, precancerous lesions such as leukoplakias or erythroplakias and chronic ulcerations of unknown cause. It is also indicated for the histological confirmation of certain systemic disorders (Fig.1) and is recommended for apparently inflammatory lesions that do not improve within two weeks of removal of local irritants.

Other lesions that should also be biopsed include:

- lesions that interfere with oral function, such as fibrous hyperplasias and osseous lumps.
- lesions of unclear aetiology, particularly when associated with pain, paraesthesia or anaesthesia
- interstitial lesions in lingual, buccal or labial muscles
- radiolucent or radio-opaque osseous lesions.

### **When is oral biopsy not needed?**

- There is no need to biopsy normal structures
- There is no need to biopsy irritative/traumatic lesions that respond to the removal of a presumed local irritant

- There is no need to biopsy inflammatory or infectious lesions that respond to specific local treatments, as pericoronitis, gingivitis or periodontal abscesses
- No incisional biopsies should be performed on suspected angiomatous lesions.

### **Types of biopsy**

According to the procedures applied, oral biopsies can be classified by:

- a) Features of the lesion:
  - direct biopsy: when the lesion is located on the oral mucosa and can be easily accessed with a scalpel from the mucosal surface.
  - indirect biopsy: when the lesion is covered by an apparently normal oral mucosa
- b) Area of surgical removal:
  - incisional biopsy: consists of the removal of a representative sample of the lesion and normal adjacent tissue in order to make a definitive diagnosis before treatment.
  - excisional biopsy: is aimed at the complete surgical removal of the lesion for diagnostic and therapeutic purposes. This procedure is elective when the size and location of the lesion allows for a complete removal of the lesion and a wide margin of surrounding healthy tissue (Fig.2).
- c) By the timing of the biopsy:
  - Pre-operative
  - Intra-operative
  - Post-operative when aimed at checking the efficiency of a treatment.

### **General principles of oral biopsy:**

Before the procedure is undertaken, the characteristics of the lesion (size, shape, colour, texture, consistency, time of evolution, associated signs and symptoms, regional nodes) should be described in the patient's clinical records together with a presumed diagnosis and possible differential diagnosis.

The patient should receive information on the technique that will be performed and the reasons why it is performed, avoiding terms that may cause anxiety. Informed consent is required.

Regarding the surgical technique:

- Regional block local analgesia rather than infiltrative techniques is preferred;
- elliptical incisions should be attempted in order to ease suture;
- incisions parallel to nerves and vases are preferred;

- if the lesion is smaller than 1 cm, excisional biopsy should be performed. If larger, an incisional technique including representative areas of the lesion with healthy margins should be chosen;
- when a malignant lesion is suspected, incisional technique is mandatory.

Samples must be oriented with a suture or a piece of paper, and introduced in a container with a fixing solution (10% formalin) (Fig.3)

The number and location of the biopsies will be decided on the basis of the clinical appearance of the lesion. If a lesion shows several areas where biopsy would be indicated, more than one sample should be taken. In these cases with precancerous or suspicious lesions, toluidine blue staining could be useful to choose the areas most relevant to biopsy.

The biopsy should be large enough to include normal and suspicious tissue and for the pathologist to give a diagnosis without further specimens (small samples are difficult to orientate and handle and certain processes as sample fixation may end in a reduction of the size of the specimen).

There are different procedures for undertaking oral biopsies. However, the selection of both technique and surgical instruments to use to avoid artefacts is controversial. The use of CO<sub>2</sub> laser for the procurement of diagnostic biopsy specimens is compromised by thermal cytological artefacts. Problems of this nature are also witnessed with electrocautery. Punch biopsy has been suggested to reduce artefacts (Fig.4), although this has not been confirmed under controlled experimental conditions. Punch biopsy may tear the tissue in vesiculobullous conditions. Scalpel biopsy is the most widely accepted technique and the one that shows fewer limitations for obtaining samples from the oral cavity.

### **Scalpel technique for biopsy taking:**

In order to obtain good visibility, good illumination is needed. A Farabeuf-type separator or similar instrument to retract the lips and cheeks, and moderate-volume surgical aspiration are required.

The instruments suggested are:

- Cartridge-type local anaesthetic syringe
- Fine, single use, two-sided needles
- Cartridges of local anaesthetic solution
- Small and short scalpel blades (no. 15, 11, 12 or even 5)
- Mosquito forceps
- Allis tweezers
- 2/0 to 5/0 non-traumatic suture material

- Gauze
- Container with fixing solution

A biopsy technique can be reduced to six steps: selection of the area to biopsy, preparation of the surgical field, local anaesthesia, incision, handling of the specimen and suture of the resulting wound.

### 1. Selection of the area to biopsy

When dealing with small-sized lesion, an excisional biopsy will be performed, whereas incisional biopsy performed in the most representative area of the lesion is used for large lesions (long axis larger than 1 cm). If there is any doubt about the malignant character of the lesion, vital staining with toluidine blue can be use as an adjunct to select representative areas (Fig.5). Toluidine blue is a basic dye that fixes to nucleic acids and stains the nuclear content of malignant cells; in these cases samples should be taken from areas with deep blue patches, as light blue areas are not significant.

Toluidine blue is used in three steps:

- wash the area with 1% acetic acid
- apply a 1% toluidine blue water solution for 1 minute
- mouthwash with 1% acetic acid

The sample must include healthy tissue at the margin of the lesion.

### 2. Preparation of the surgical field.

The surgical area is disinfected with a quaternary ammonium compound. Iodine-containing surface antiseptics should not be used, as they may stain the tissues. A 0.12- 0.20 % chlorhexidine solution is preferred.

### 3. Local anaesthesia:

An amide-type local anaesthetic with vasoconstrictor should be used and infiltrated away from the lesion are to avoid introducing artefacts in the sample.

### 4. The incision:

Oral tissues should be immobilized far from the area to biopsy with non-toothed tweezers. A clean and defined incision is performed to obtain a slice of tissue when aiming at incisional biopsy. Soft tissues incisions should be elliptical in shape producing a "V" wedge that includes both the lesion and healthy margins. If various lesions are present, multiple biopsies should be taken.

## 5. Tissue handling

The specimen is handled gently to avoid crush artefacts and introduced in the fixing solution. The role of the fixing agent is to preserve the cellular architecture of the tissues. There are authors that suggest the placement of the specimen on a sterile paper with the mucous surface facing upwards to avoid distortion and curling of the sample margins.

The best fixing agent is a 10% formalin solution, as it induces less ultrastructural alterations in the samples. 70% ethanol can also be used. The samples should never be put in isopropyl or methyl alcohol, saline or distilled water - as severe alterations may be provoked.

The volume of the fixing agent should exceed 10 to 20-fold the volume of the sample. When immunofluorescence or immunostaining are needed, specimens should not be fixed, but sent as soon as possible to the laboratory for freezing or put in Michel's solution.

When the material is sent to the pathologist, it should be accompanied with a detailed report that includes identification of the patient, clinical records, clinical signs and a probable diagnosis as well as the orientation of the sample. An explanatory diagram of the biopsy area may be useful for this purpose.

## 6. Suture

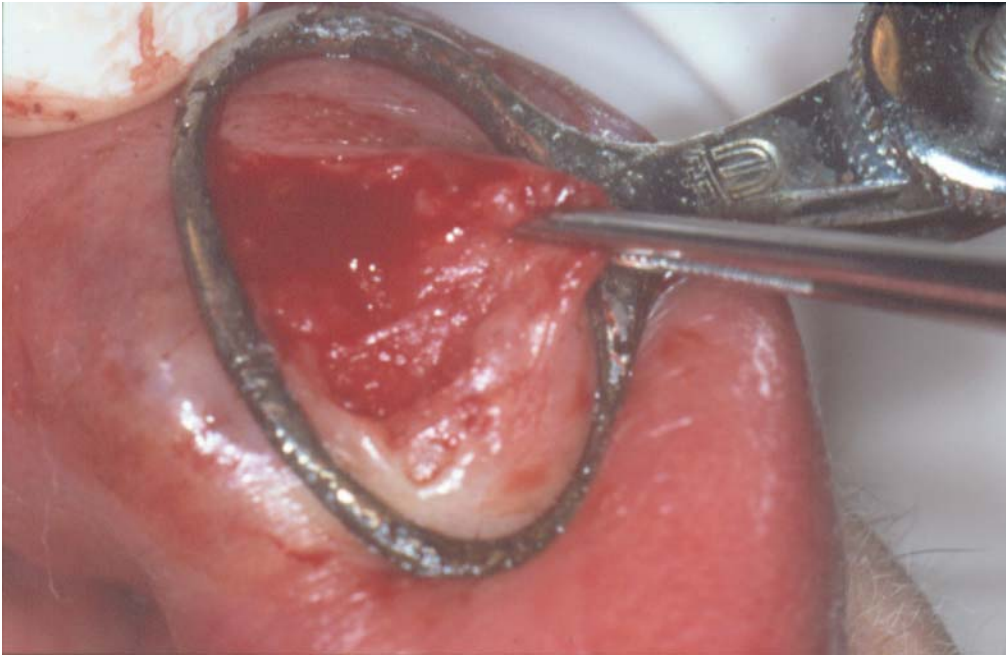
The suture should achieve good haemostasis, facilitate healing and should be removed after 6-8 days

### **What are the most frequent errors that should be avoided when taking oral biopsies?**

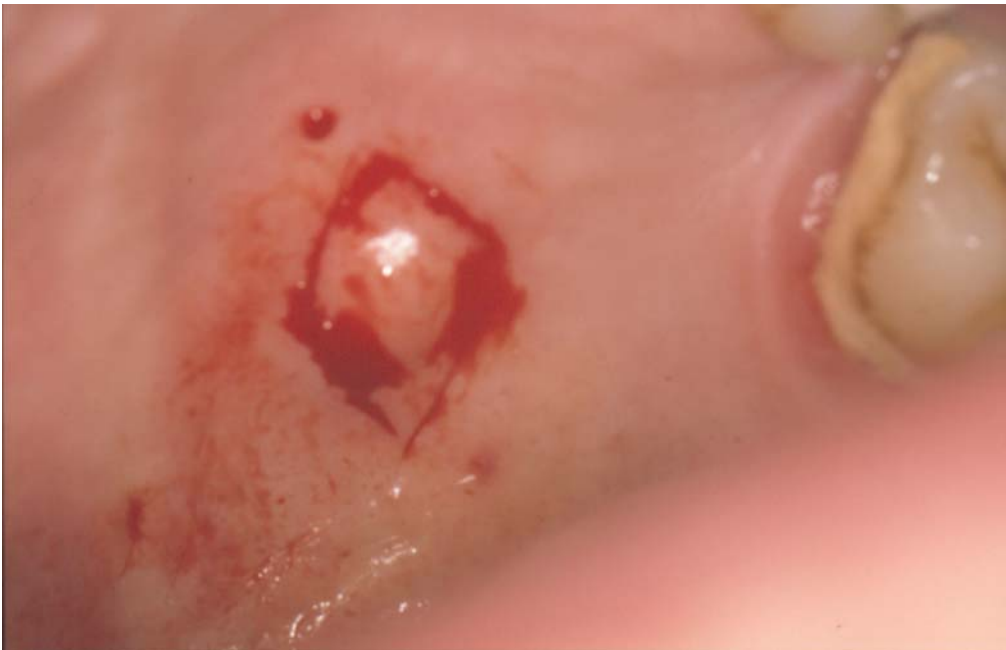In order to obtain a quality, artefact-free oral biopsy that permits the pathologist establish a histological diagnosis, the clinician should avoid:

- pressing the sample with the tweezers, particularly if toothed, as may produce tissue tears and "pseudomicrocysts"
- infiltrating anaesthetic solution within the lesion, as it can cause sample alterations
- applying products to the lesion that induce tissue modifications
- using an insufficient volume of fixing solution
- inclusion of undesired material in the sample: glove powder, calculus, restorative materials, etc.
- taking insufficient amount of tissue in extension and depth.

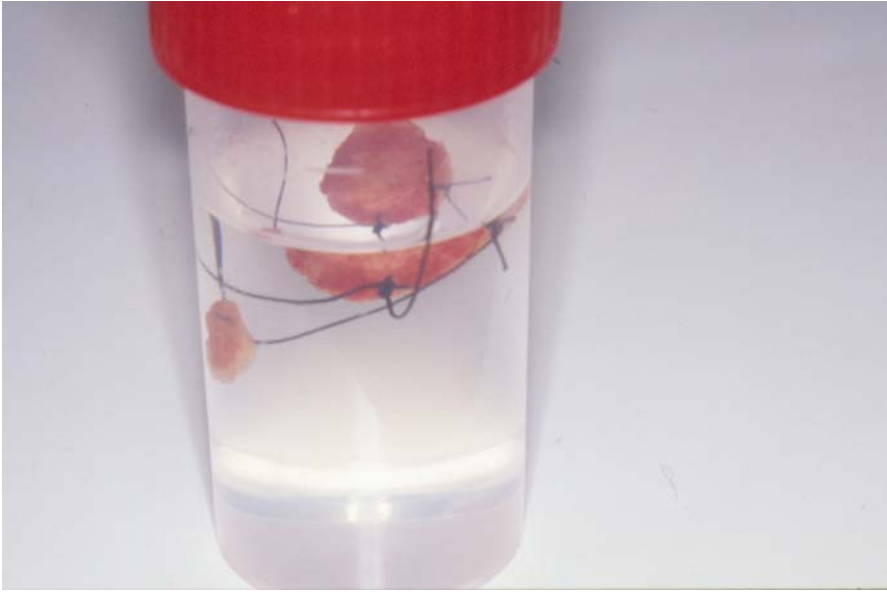**Pictures:**



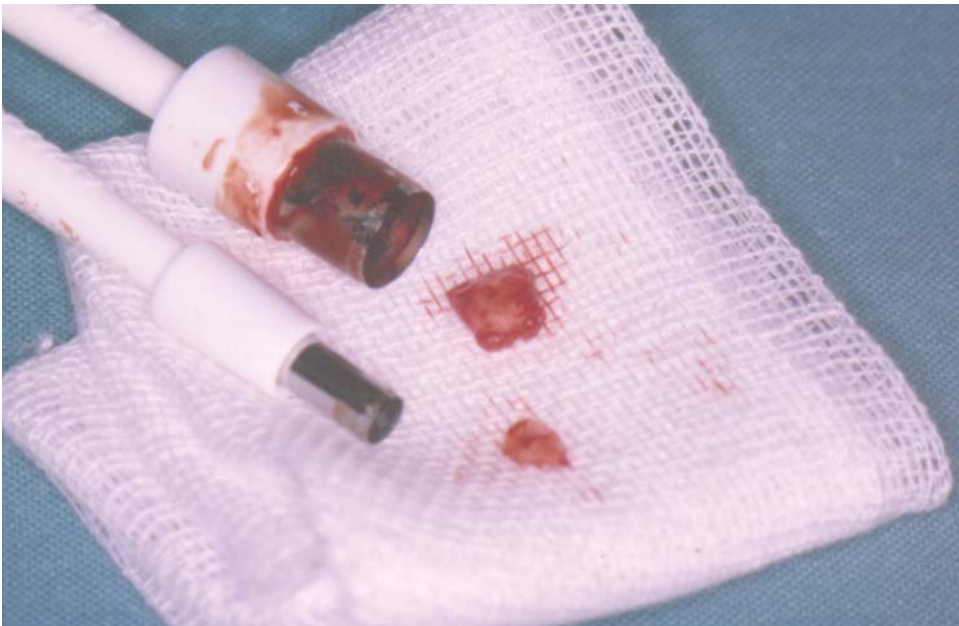**Figure 1.** Biopsy of minor salivary glands for diagnosis of Sjögren syndrome.



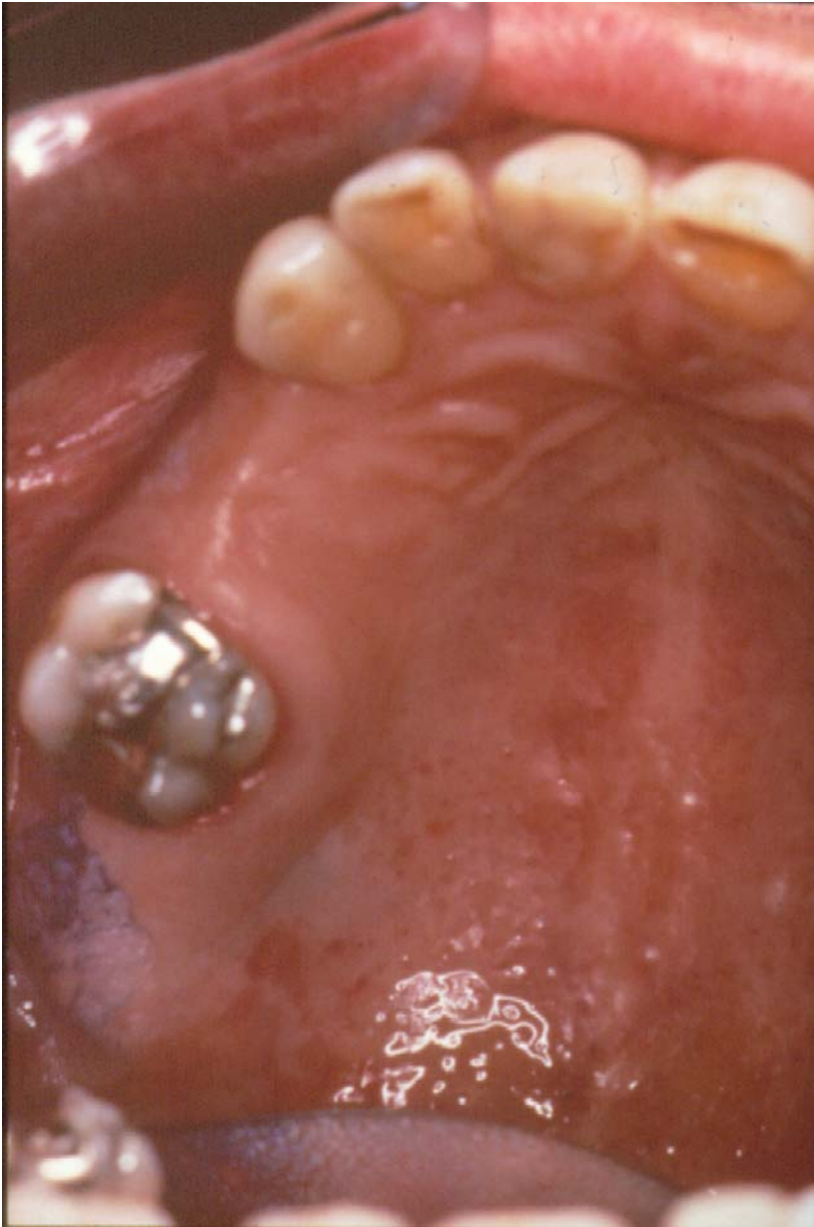
**Figure 2.** Excisional biopsy of a nodular lesion of the palate.



**Figure 3.** Container with a fixing solution.



**Figure 4.** Specimens obtained by punch biopsy.



**Figure 5.** Toluidine blue is used to select the representative areas.



### **Further reading**

- 1 Eversole LR . Laser artefacts and diagnostic biopsy. Oral Surg Oral Med Oral Pathol 1997; 83:639-641.
- 2 Gould AR. Early detection of oral premalignant disease and oral cancer: Refining the process. Oral Surg Oral Med Oral Pathol 2002; 94:397-398.
- 3 Kahn MA, Lynch DP, Turner JE, Mincer HH. The dos and don'ts of an oral mucosal biopsy performed by the general dentist. J. Tenn. Dent. Assoc 1998; 78,28-31.
- 4 McAndrew PG. Oral cancer biopsy in general practice. Br Dent J 1998; 185:428.
- 5 Seoane J, Varela-Centelles P, Ramirez JR, et al . Artefacts produced by suture traction during incisional biopsy of oral lesions. Clin Otolaryngol 2002; 27:549-553.

### **Links**

[http://www.eastman.ucl.ac.uk/~eaom/clinical\\_support.html](http://www.eastman.ucl.ac.uk/~eaom/clinical_support.html)